

MINIMALLY INVASIVE GUIDED BONE REGENERATION

Efraim Kfir, DDS; Vered Kfir, DDS; Eli Eliav, DMD, PhD; Edo Kaluski, MD

Guided bone regeneration (GBR) is indicated when there is a volume deficiency of the residual ridge that prohibits implantation or optimal implant installation for esthetic and functional needs. Our objective is to describe a new minimally invasive GBR and report its clinical application in several patients. A vertical incision is made mesial to the augmentation zone. The periosteum is initially elevated with a miniature chisel, and then through a series of sequential balloon inflations. This yields a tunnel with adequate space for membrane insertion, decortication, and grafting with substitute bone and platelet rich fibrin (PRF) filling. Primary closure is obtained by 2 or 3 simple interrupted sutures. Vertical and horizontal gains were measured on computerized tomography obtained before and 5 to 6 months after the procedure. Eleven patients were treated with this procedure. There were no significant adverse events. The range of vertical gain was 2.4 to 5.1 mm, while horizontal gain measured 1.3 to 3.9 mm. Implants were successfully placed in 6 patients.

Key Words: guided bone regeneration, tunneling, bone augmentation

INTRODUCTION

Conventional guided bone regeneration (GBR)¹ is performed via a horizontal incision along the alveolar crest, with two oblique vertical incisions and release of the periosteum. Placement of any barrier membrane², corticocalcaneous autografts,³⁻⁴ or demineralized freeze-dried bone⁵⁻⁶ to optimize GBR can potentially result in excessive tissue volume that, along with the procedural edema and inflammation, exerts tension on the suture line. Reported methods to alleviate tension over the suture line include overlapping the flap, positioning the flap

laterally, tissue grafting, or using a combination of mattress sutures and interrupted sutures. Despite these surgical techniques, this procedure may still be associated with excessive tension on the suture line, which can often result in suture line opening and early membrane exposure and infection.^{3,7-8} Complete tension-free primary closure is essential to prevent these complications.⁹ While the effects and impact of early membrane exposure are controversial, most clinicians would agree that this complication warrants meticulous oral hygiene and frequent patient follow-up. Early membrane removal can result in reduced bone fill¹⁰ and the presence of infection can cause additional bone loss.¹¹⁻¹² Some authors^{3,13} believe that early membrane exposure without infection does not have a profound effect on GBR and should be managed with thorough plaque control. Regardless of the eventual consequences, the consensus is that postoperative soft tissue dehiscence is a frequent and undesirable complication of GBR.

This describes a new minimally invasive GBR technique that uses nonconventional incision lines, along with balloon-assisted elevation of the periosteum, and reports its clinical application in several patients.

Efraim Kfir, DDS, is a private practitioner at a dental clinic in Petah-Tikvah, Israel.

Vered Kfir, DDS, is a private practitioner at a dental clinic in Kupat Holim Clalit, Rehovot, Israel.

Eli Eliav, DMD, PhD, is an associate professor and Robert and Susan Carmel Endowed Chair in Algesiology in the Department of Dentistry and Edo Kaluski, MD, is Director of Invasive Cardiology & Cardiac Catheterization Laboratories and an associate professor of medicine in the Department of Cardiology, University Hospital, University of Medicine and Dentistry of New Jersey, Newark, NJ. Address correspondence to Dr. Kaluski at University Hospital, UMDNJ, 185 South Orange Avenue, MSB, Room I-538, Newark, NJ 07101 (e-mail: ekaluski@gmail.com).

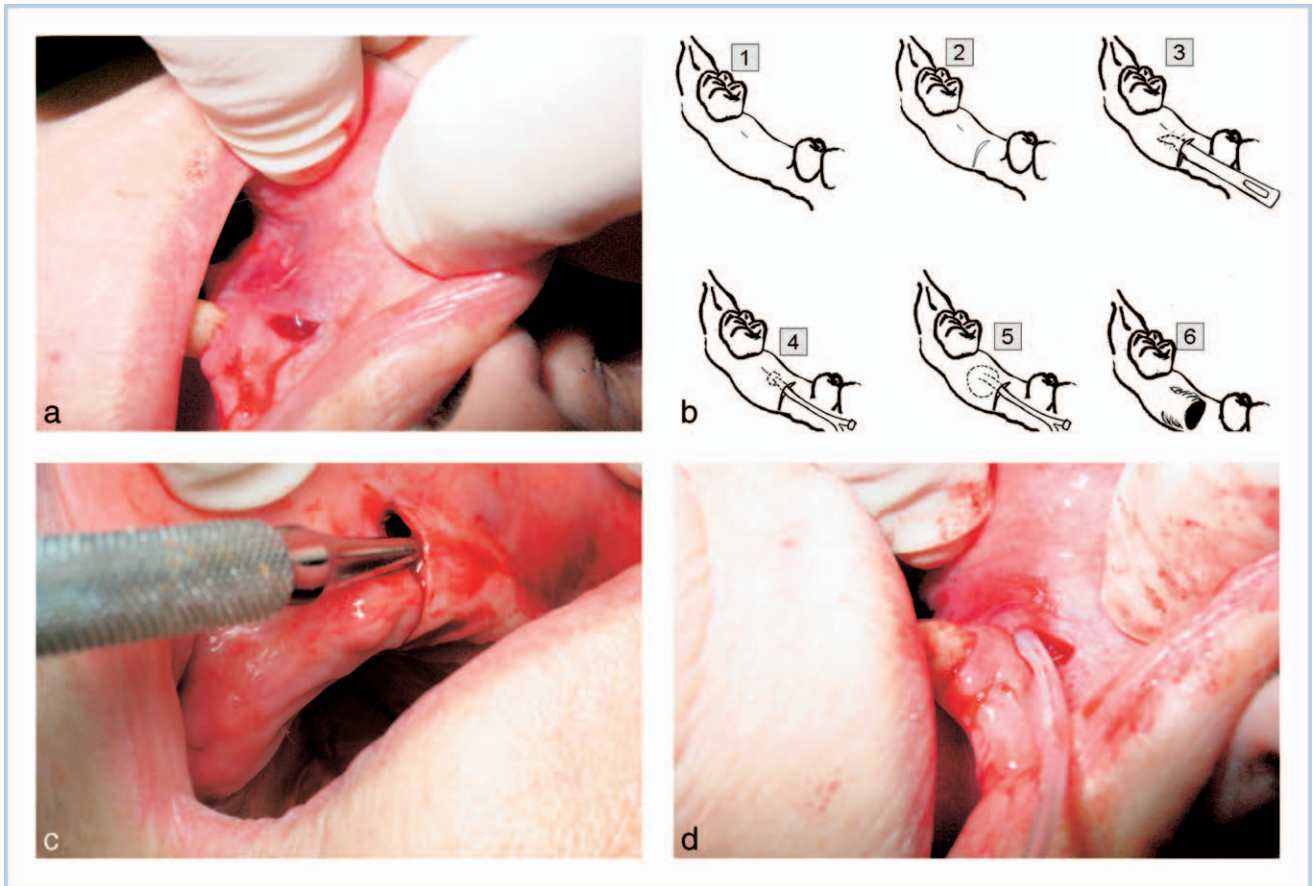


FIGURE 1. (a) Vertical incision. (b) The incision. (c) Chisel widening. (d) Balloon inflation.

MINIMALLY INVASIVE TECHNIQUE

Patients

This technique is indicated for partially or completely edentulous healthy adults, with insufficient localized jaw bone volume to receive dental implants. Presurgical radiographic evaluation is used to determine the severity of ridge resorption (CT, panoramic, and periapical radiograms) followed by clinical examination to evaluate the type of gingiva (attached or mobile). The patients should receive a detailed explanation regarding the technique and sign an informed consent prior to the procedure.

Equipment and materials

- Silicone catheter (Pediatric 6F Foley catheter, Rochester Medical Corporation, Stewartville, Minn)
- Bio-degradable (GTR) membrane (Inion, Tampere, Finland)
- Inflation syringe (BASIX 25, Merit Medical, Galway, Ireland) filled with diluted contrast material (50% Ultravist 370 by Schering AG, Berlin, Germany)

- Autologous fibrin obtained by centrifugation of 40 mL autologous blood divided into 4 test tubes and spun for 10 minutes at 2700g.
- Synthetic bone graft material (BiOstetic, Berkeley Advanced Biomaterials Inc., San Leandro, California)

Procedure

A nonsteroidal anti-inflammatory agent (eg, celecoxib 200 mg daily) and antibiotic such as amoxicillin and clavulanate potassium (Augmentin 875, SmithKline Beecham Healthcare Ltd., Brentford, England) twice daily are initiated 24 hours prior to the procedure.

The membrane was prepared according to the manufacturer's instruction. Measurements of the desirable GBR area are obtained by radiographic and clinical measurements. Nitrous oxide gas may be used with local anesthesia (eg, Articain 4%, such as Ubistesin Forte 3M ESPE Dental, Seefeld, Germany). The latter was administered via infiltration of the buccal and palatal regions in the upper jaw, and

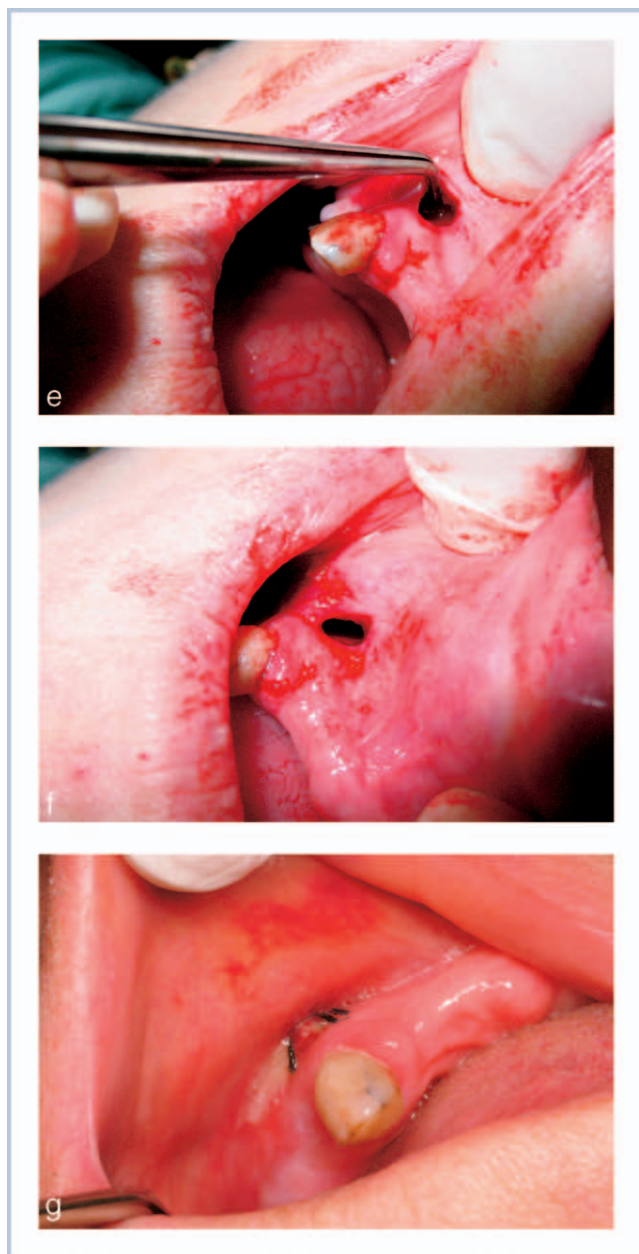


FIGURE 1 CONTINUED. (e) Tunneling acquisition. (f) Membrane insertion. (g) Suture closure.

inferior mandibular, lingual, and long buccal blocks in the lower jaw.

A vertical full-thickness incision is done in the mesial aspect of the augmented ridge (Figure 1a) from the free gingiva to beyond the mucogingival junction (MGJ). In completely edentulous ridge, the incision was extended 3 mm toward the palatal in the maxilla and up to the alveolar crest in the mandible (Figure 1b).

A dedicated mini-chisel is inserted through the incision between the bone and the periosteum (Figure 1c) and advanced to gently release the periosteum

from the bone. Using this technique, the chisel was moved from the alveolar crest to beyond the MGJ, until the distal border of the desired GBR segment is reached. Once an initial tunnel has been created, the Foley catheter is placed into the targeted GBR zone. The balloon is inflated with a dedicated inflator to a pressure of 2 atmospheres (Figure 1d). Sequential inflations are executed from distal to proximal. When the initial tunneling was completed (Figure 1e), the periosteum was further released beyond the alveolar crest from both the palatal and lingual aspects. Extreme caution must be exercised to avoid tissue perforation during these maneuvers.

The membrane was trimmed to the desirable dimensions, then placed into the tunnel and adjusted to cover both buccal and palatal (or lingual) surfaces of the bone (Figure 1f). Membrane stiffness increases as soon as it absorbs any fluid. The margins of the membrane should be >3 mm away from the incision. A pouch was created between the bone and the membrane. Using a straight hand-piece with a small rounded diamond bur, several decortications were made to achieve inductive bone cells from the marrow space. A mixture of autologous fibrin obtained from patient's centrifuged blood and bone graft substitute is inserted into the tunnel until the desirable ridge dimensions are obtained.

The incision was closed with 2 to 3 simple sutures (Figure 1g), and the membrane is secured by a suture to the tissue to prevent any mobility. Patients were instructed to wash the mouth with chlorhexidine 0.2% twice daily, continue antibiotic therapy for 7 days, and avoid prosthesis use and chewing or brushing the affected area for ≥ 2 weeks. Sutures may be removed after soft tissue healing approximately 10 days after surgery.

CLINICAL APPLICATION

Between May 2005 and May 2006, 11 patients underwent this surgical procedure. Mean age was 54 years (range, 32 to 76). After 5 to 6 months, patients underwent a second computerized tomogram. Three measurements of height and width were obtained (medial, mid, and lateral) for each tooth location and a mean of these measurements was calculated. There were no perioperative or postoperative complications. All procedures resulted in major swelling of the surgical region, but only a minor degree of transient pain and disability.

Measurements of osseous structures obtained before surgery and at 6 months postoperative are summarized in the Table. Six patients received dental

TABLE
Primary end points: guided bone regeneration (GBR) results

Patient number	Region	Height before (mm)	Height after/gain (mm)	Width before (mm)	Width after/gain (mm)	Implant length (mm)	Implant diameter (mm)	GBR to implant interval (months)
1	46	9.5	13.5/4	4.5	7.3/2.8	12	4.1	6
	47	6.1	11.2/5.1	4.6	8.4/3.9	10	4.1	
2	34	11	14.1/3.1	2.5	5/2.5	13	3.3	4.5
	36	8.6	11/2.4	3	6/3	10	4.1	
3	37	6.6	10.1/4.6	5	7/2	None	None	6*
4	35	7.3	12.2/4.9	3.5	4.8/1.3	None	None	6*
	36	7	10.1/3.1	3.3	6.3/3			
5	13	9.7	13.6/3.9	2.3	5.8/3.5	13	3.75	6
	14	10.1	14/3.9	2.7	5.4/2.7	13	3.75	
6	36	11	14/3	3.5	6/2.5	None	None	12*
	37	10	15/5	5.5	9/3.5			
7	14	9.4	13.9/4.5	2.4	5.3/2.9	13	3.75	5
	15	9.5	14.1/4.6	2.5	5.5/3.0	13	3.75	
	16	9.7	13.9/4.2	3.7	6.1/4.4	13	3.75	
8	45	10.4	12.8/2.4	2.3	4.8/2.5	12	3.75	7
9	46	9.3	14.1/4.0	3.5	6.3/2.8	13	5	6
	47	8.9	13.9/4.0	2.8	6.1/3.3	13	4.2	
10	46	11.5	14.9/3.4	3.3	6.5/3.2	None	None	6*
	36	11.2	14.5/3.3	3.1	5.7/2.6	None	None	
11	37	7.5	11.4/3.9	4.4	6.2/1.6			6*

*Follow-up without implantation.

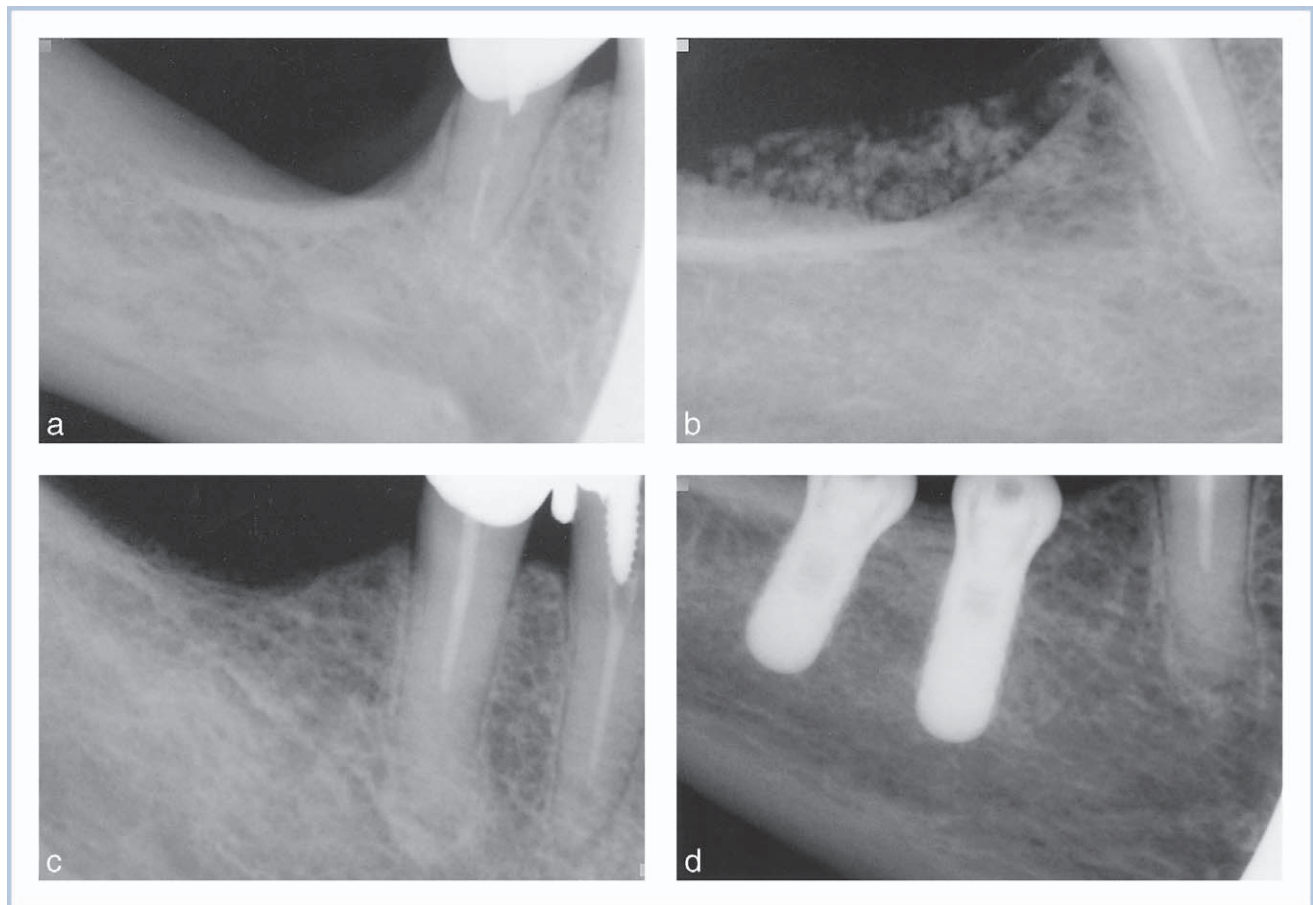


FIGURE 2. (a) Pre-guided bone regeneration (GBR). (b) Immediately post-GBR. (c) Six months post-GBR. (d) Implant fixation.

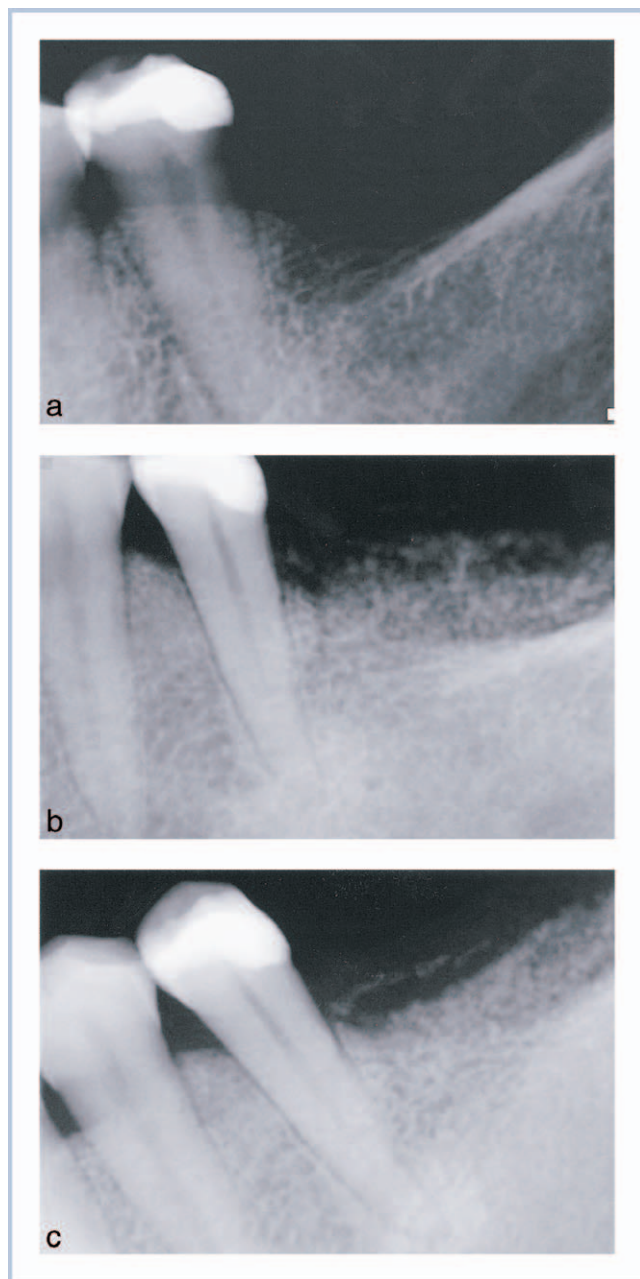


FIGURE 3. (a) Pre-guided bone regeneration (GBR). (b) Immediately post-GBR. (c) Six months post-GBR.

implants as indicated in the Table. There were no adverse events involving membrane exposure, tissue dehiscence, infection, or implant failure (Figures 2a through 2d and Figures 3a through 3c).

DISCUSSION

This article presents a “tunneling” that allows performing GBR by creating a relatively small vertical incision, as opposed to traditional horizontal incisions. After a

series of balloon dilatations, it is possible to place an adequately sized barrier membrane with autologous fibrin and bone graft substitute through this small incision. Primary closure without tension on the suture line is easily accomplished with this small vertical incision. Suture line opening and early membrane exposure observed frequently after primary closure using horizontal incisions has not been observed by the authors, and no apparent limitations or shortcomings of this method have been experienced. The literature reports successful GBR using PTFE,^{14–15} collagen,^{16–17} and titanium mesh. Additional research is needed to determine which augmentation materials may be more beneficial using this technique.

NOTE

The authors of this manuscript have no financial association that might pose a conflict of interest in connection with the submitted proposal.

REFERENCES

1. Buser D, Dula K, Hirt HP, Schenk RK. Lateral ridge augmentation using autografts and barrier membranes: a clinical study with 40 partially edentulous patients. *J Oral Maxillofac Surg.* 1996;54(4):420–432.
2. Hermann JS, Buser D. Guided bone regeneration for dental implants. *Curr Opin Periodontol.* 1996;3:168–177.
3. Mellonig JT, Triplett RG. Guided tissue regeneration and endosseous dental implants. *Int J Periodontics Restorative Dent.* 1993;13(2):108–119.
4. Kaufman E, Wang PD. Localized vertical maxillary ridge augmentation using symphyseal bone cores: a technique and case report. *Int J Oral Maxillofac Implants.* 2003;18(2):293–298.
5. Simion M, Dahlin C, Trisi P, Piattelli A. Qualitative and quantitative comparative study on different filling materials used in bone tissue regeneration: a controlled clinical study. *Int J Periodontics Restorative Dent.* 1994;14(3):198–215.
6. Feuille F, Knapp CI, Brunsvold MA, Mellonig JT. Clinical and histological evaluation of bone-replacement grafts in the treatment of localized alveolar ridge defects. Part 1: mineralized freeze-dried bone allograft. *Int J Periodontics Restorative Dent.* 2003;23(1):29–35.
7. Becker W, Dahlin C, Becker BE, Lekholm U, van Steenberghe D, Higuchi K, Kultje C. The use of e-PTFE barrier membranes for bone promotion around titanium implants placed into extraction sockets: a prospective multicenter study. *Int J Oral Maxillofac Implants.* 1994;9(1):31–34.
8. Becker W, Dahlin C, Lekholm U, Bergstrom C, van Steenberghe D, Higuchi K, Becker BE. Five-year evaluation of implants placed at extraction and with dehiscences and fenestration defects augmented with ePTFE membranes: results from a prospective multicenter study. *Clin Implant Dent Relat Res.* 1999;1(1):27–32.
9. Nemcovsky CE, Artzi Z. Comparative study of buccal dehiscence defects in immediate, delayed, and late maxillary implant placement with collagen membranes: clinical healing

between placement and second-stage surgery. *J Periodontol.* 2002; 73(7):754–761.

10. Simion M, Baldoni M, Rossi P, Zaffe D. Comparative study of GTAM membrane without early exposure during the healing period. *Int J Periodontics Dent.* 1994;14(2):167–180

11. Moses O, Pitaru S, Artzi Z, Nemcovsky CE. Healing of dehiscence-type defects in implants placed together with different barrier membranes: a comparative clinical study. *Clin Oral Implants Res.* 2005;16(2):210–219.

12. Gher ME, Quitero G, Sandiper JB, Tabacco M, Richardson AC. Combined dental implant and guided tissue regeneration therapy in humans. *Int J Periodontics Restorative Dent.* 1994; 14(2):333–347

13. Dahlin C, Lekholm U, Becker W, Becker B, Higuchi K, Callens A, Van Steenberghe D. Treatment of fenestrations and dehiscence bone defects around oral implants using guided tissue regenera-

tion technique: a multicenter prospective study. *Int J Oral Maxillofac Implants.* 1995;10(3):312–318

14. Buser D, Dula K, Hirt HP, Schenk RK. Lateral ridge augmentation using autografts and barrier membranes: a clinical study with 40 partially edentulous patients. *J Oral Maxillofac Surg.* 1996;54(4):420–432.

15. Artzi Z, Zohar R, Tal H. Periodontal and peri-implant bone regeneration: clinical and histologic observations. *Int J Periodontics Restorative Dent.* 1997 Feb;17(1):63–73.

16. Proussaefs P, Lozada J. The use of resorbable collagen membrane in conjunction with autogenous bone graft and inorganic bovine mineral for buccal/labial alveolar ridge augmentation: a pilot study. *J Prosthet Dent.* 2003;90(6):530–538.

17. Wang HL, Carroll MJ. Guided bone regeneration using bone grafts and collagen membranes. *Quintessence Int.* 2001; 32(7):504–515.